

# Sternum Instability in Clinical Practice

Hans Jonsson M.D Ph.D.

Department of Cardiothoracic Surgery and Anesthesiology

Karolinska University Hospital

Is that a problem in open  
heart surgery?

Yes!!

# Sternum Instability

We must stabilize sternum much better!

# Sternum Instability

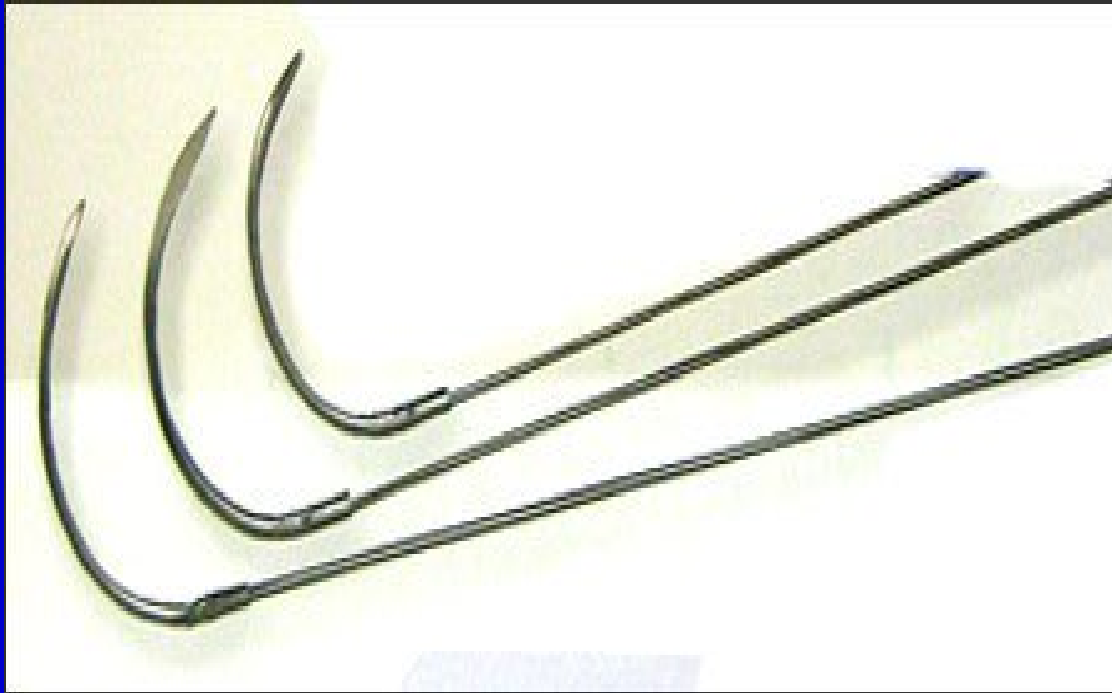
- There are different ways in stabilizing the sternum perioperatively
- steelwires
- plastic bundles
- osteoplates

# Sternum Instability

-We must treat our sternumfracture in the same way as the ortopedic surgeon treat their fractures.

- Reposition
- Stabilisation
- Rehabilitation

# Sternum Instability

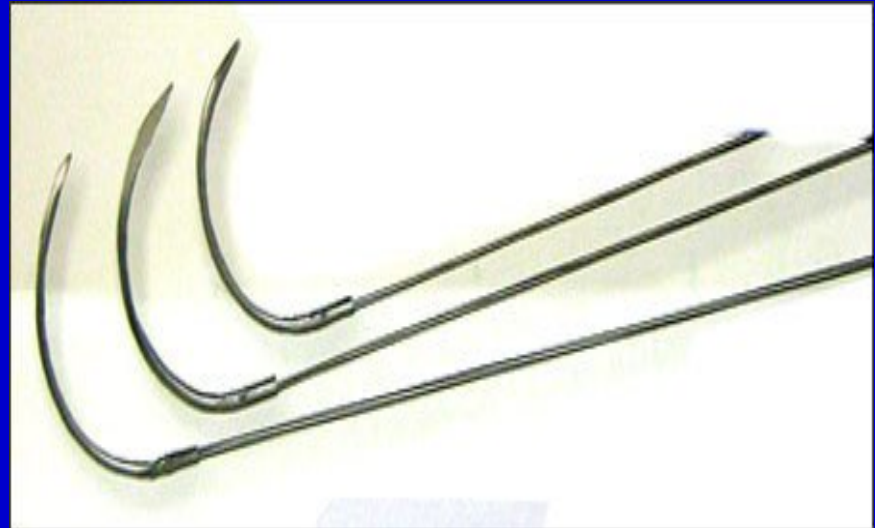


## Sternum Instability

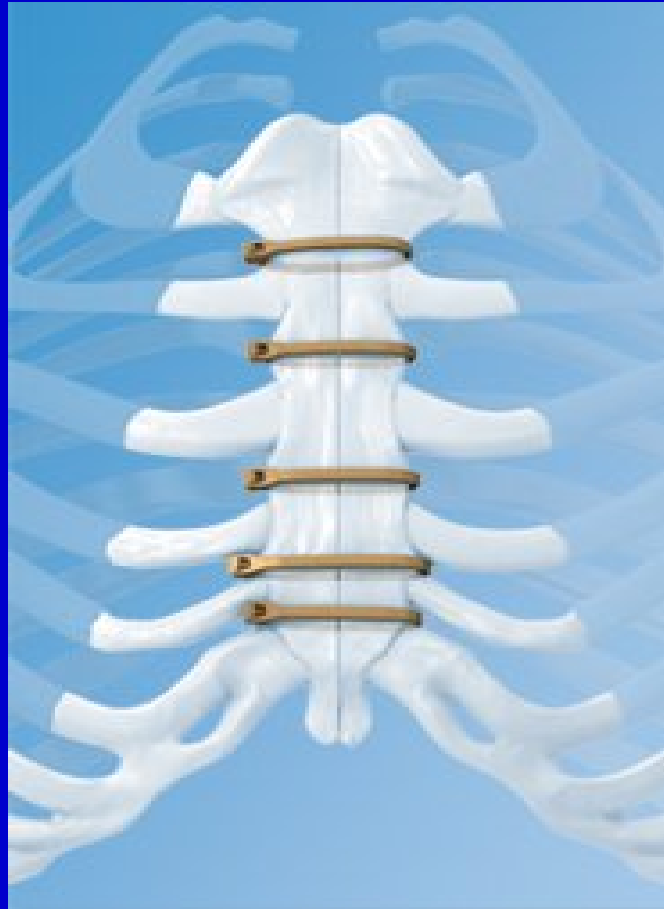Steelwires- different kinds of steelwires

Does it stabilise the sternum ?

How many wires?

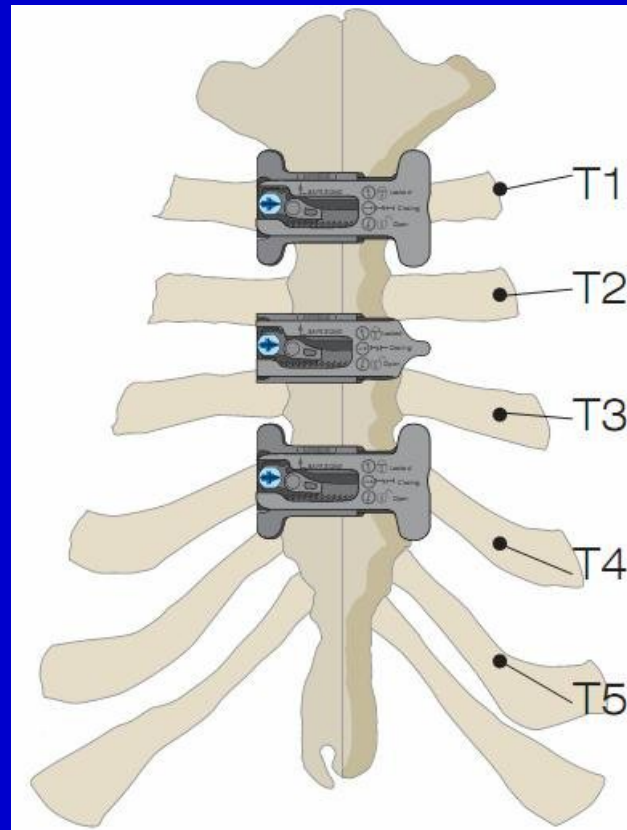


# Sternum Instability

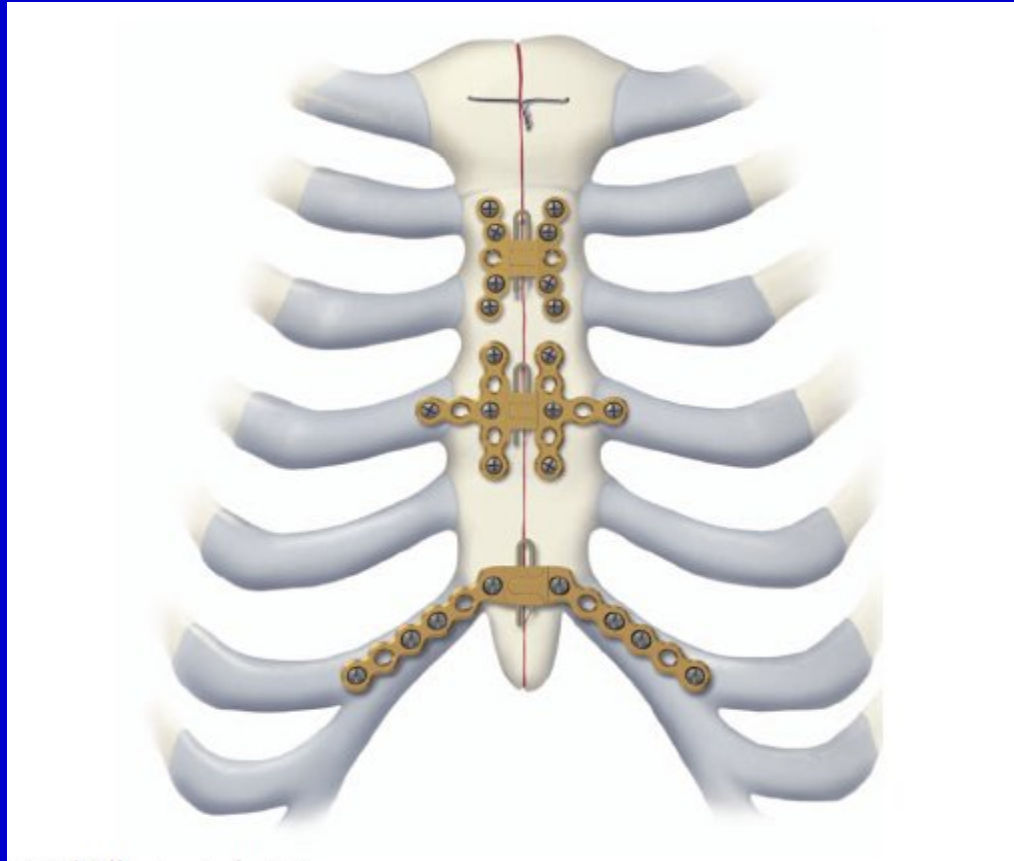




# Sternum Instability



# Sternum Instability



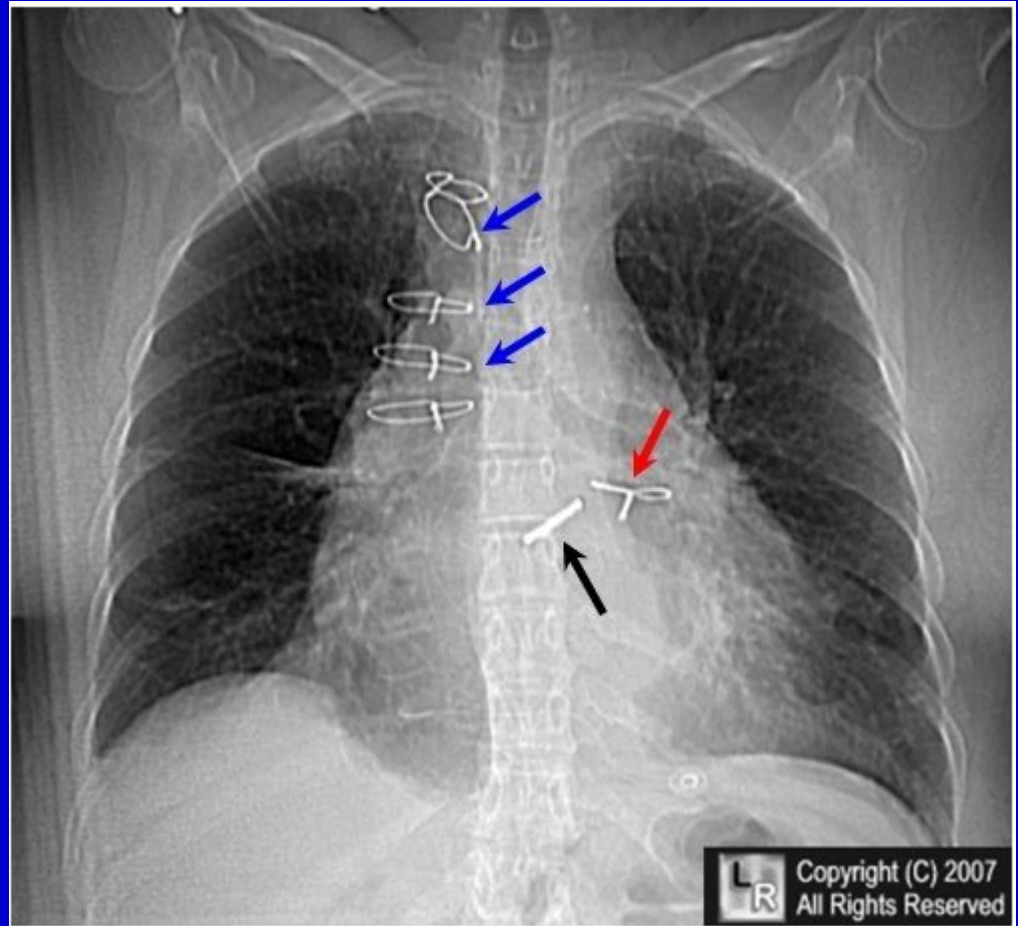
# Sternum Instability

- Sternal dehiscence is a major cause of morbidity and mortality in open heart surgery.
- A feared complication is mediastinitis, more than 2/3 of the patients have sternal dehiscence.
- Coagulase negative Staphylococci were isolated in 55% of those with S. dehiscence compared to 26% with stable sternum.
- High BMI (>30) and COPD were associated with CNS

# Sternal Instability

-**Sternal dehiscence.** The blue arrows point to one group of sternal wires that are displaced to the right of the midline while the red arrow points to a lower wire that has traveled with the left half of the dehisced sternum

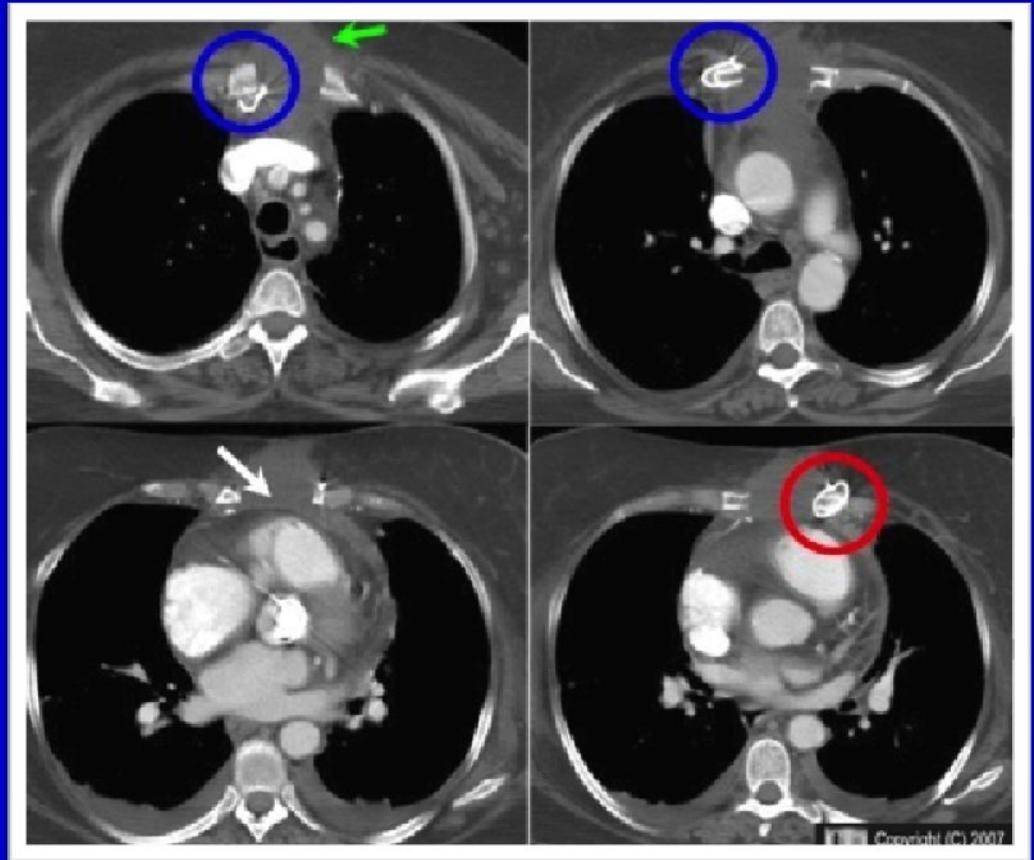
-*American Journal of Roentgenology, Vol 173, 777-780*



## Sternal Instability

-The sternum has separated (white arrow) with some of the wires attached to the right half (blue circles) and one of the wires attached to the left half (red circle). There is a fluid collection between the two halves of the sternum (green arrow).

*American Journal of  
Roentgenology, Vol 173, 777-780*



# Sternal Instability

- Staphylococcus aureus were isolated in 26% of the patients with S. dehiscence.
- It is more frequent among patients with stable sternum.
- Patients who had been reoperated before onset of mediastinitis tended to have an increased risk for a gram-negative etiology

# Sternum Instability

- Median time from operation to development of mediastinitis was 7 days in our material.
- Sternal dehiscence was seen in 68 %
- Coagulase negative Staphylococci (CNS) in 46 %
- Staphylococcus aureus in 26 %
- Gramnegative bacteria in 18 %
- CNS more frequent in patients with unstable sternum and S. aureus more frequent in patients with stable sternum.

# Sternum Instability

- The overall 90-day mortality was 19 %
- Three different types of postoperative mediastinitis
- Mediastinitis associated with obesity, COPD, sternal dehiscence are mainly caused by CNS
- Mediastinitis caused by perioperative contamination are mainly caused by *S. aureus*.
- M. mainly spread from concomittant infections during the postoperative period are mainly caused by gram negative rods.



# Sternum Instability

- Mediastinitis leads to a significant suffering for the patients.
- It prolongs the hospital stay 5 to 6 times, from 7 days to around 40 days.
- The cost increased from 20.000 Euro to 75.000 Euro.
- That means we have to do something about it.
- It is a win-win situation

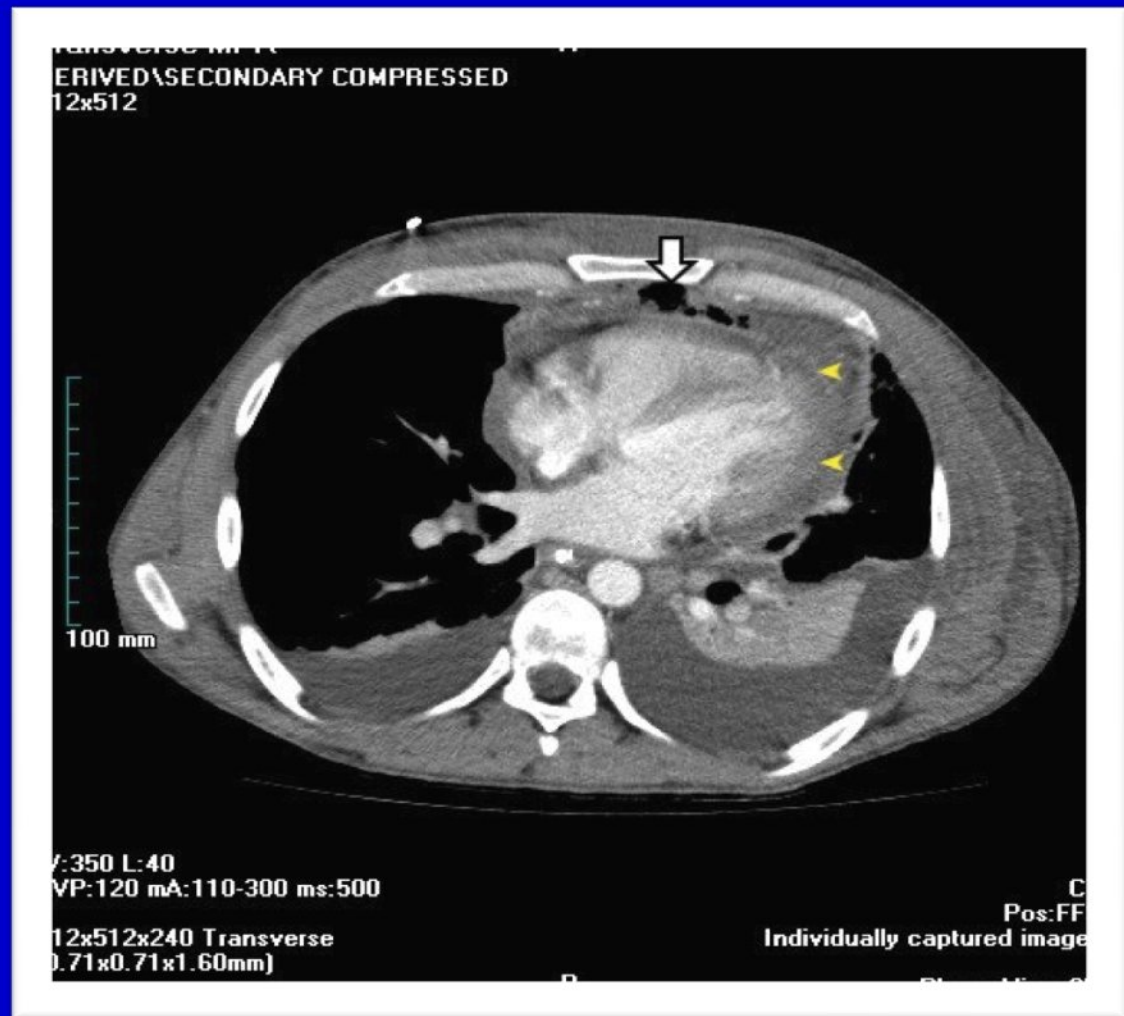
The most important thing is, reduce the suffering for the patient. And as a result of that we also decrease the cost.

## Sternum Instability

-The CT shows mediastinal gas and fluid (arrow), bilateral pleural effusions and pericardial effusion (yellow arrowheads).

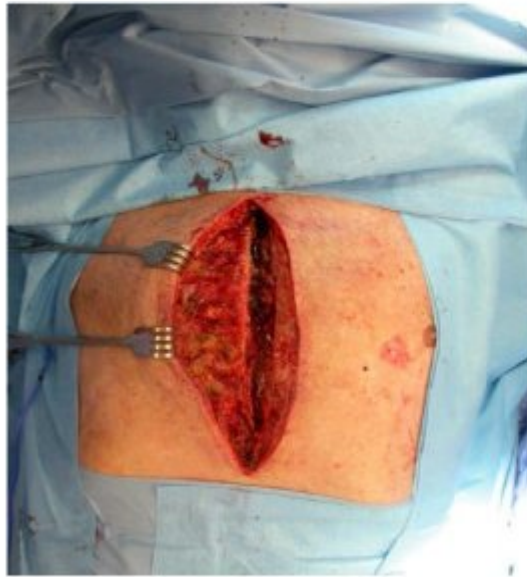-Mediastinitis may progress to abscess formation

*Diagnosis of Diseases of the Chest* W.B.Saunders 1979

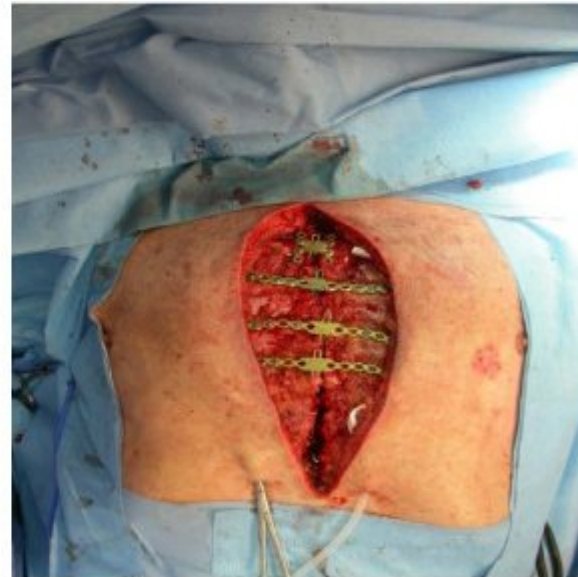

# Sternum Instability

**(A) Debridement**



**(B) Sternal Plates fixation**



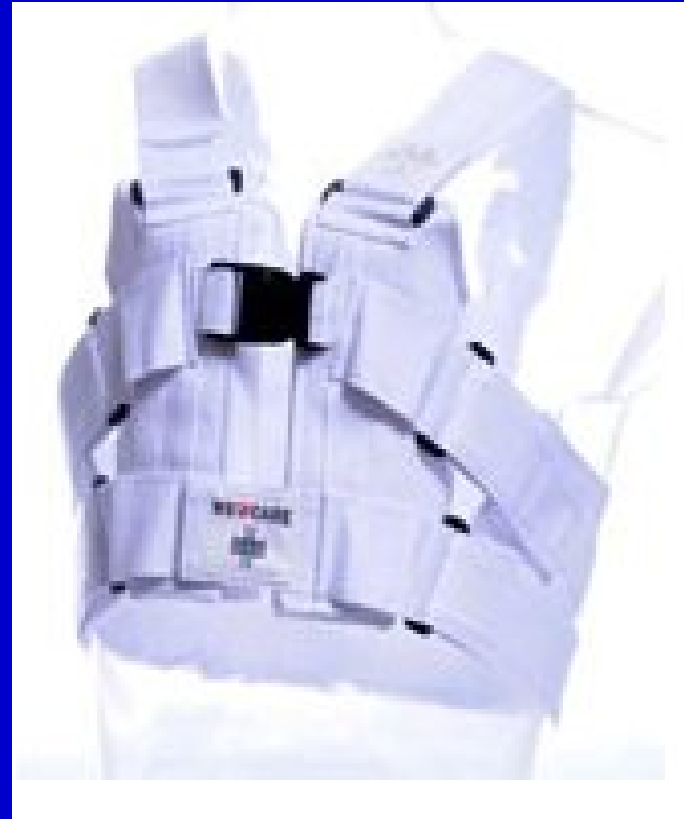# Sternum Instability

- After the operation comes a very important period. It takes approximately 6-8 weeks for the sternum to heal.
- During this time the sternum must also be stabilized, like all other fractures. We have, sorry to say, not been good in the period after operation.
- One very important factor that differ sternum fractures from other fractures is, it moves all the time due to breathing.
- In our clinic the frequency of mediastinitis varied from 1,6 to 2,5 % in the last 6 year.

## Sternal Instability

Important: The vest is fitted with the back part to rest below the shoulder blades and the two cushions high up in front, to the left and right of the sternum. Breathe in before closing the 2 side straps. Now exhale. Before closing the shoulder straps, pull the vest below the shoulder blades.

Now the two cushions should stabilize the sternum without too much pressure, to allow normal breathing and acceptable comfort. Use correct sizing



# Sternum Instability

- We started to use the Posthorax vest October 2011
- From the 1st of January to the 31st of December in 2012 we performed a midline sternotomy in 978 patient .
- 6 patients got mediastinitis
- 3 of them wore the vest according to the protocol
- It is too good to be true

## Sternum Instability

What we have seen with the west

- Our mediastinitis frequency decreased from 2,2 % in 2011 to 0,6 % in 2012!

- The frequency of atelectasis is significant lower then before

- The physioterapist says that the patients are much easier to mobilise. They do not have so much pain

- Hospital stay decreased with 1 day among women.

## Postthorax vest

